Chopart's joint

The **Chopart joint** or *articulatio tarsi transversa* is the articulation between the *talum* and the *calcaneum* with the *tarsal bones*.

Francois Chopart

It is named after the French surgeon Francois Chopart. He performed amputations in the area of the metatarsal joint in the 18th century. He himself did not write a publication about amputation, but other authors mention him in their works and thus made him famous.

General description of joint and joint line

The Chopart joint is a functional unit. It is a compound joint. The *os naviculare* and the *talus* are articulated at the *articulatio talonaviculare*. The *os cuboideum* and the *calcaneus* are joined at the *articulatio calcaneocuboidea*. Thus, the joint line is formed by the *talonavicular* fissure in the tibial part, which is convex distally, and the *calcaneocuboidea*, which is convex proximally. It resembles the letter S and is important both in terms of flexibility of the entire leg and in terms of surgical interventions. Forms a line during amputation of the distal leg *(surgical exarticulation)*.

Joint capsule and ligaments

The joint capsules are short and stiff and are reinforced by longitudinal, transverse and interosseous ligaments.

On the dorsal side:

- ***lig. talonaviculare*** (dorsal);
- ***lig. bifurcatum*** – starts from the calcaneus and splits distally into two ligaments;
  - *lig. calcaneonaviculare*;
  - *lig. calcaneocuboideum*.

After cutting the leagues. bifurcatum is a possible opening of the Chopart joint, among surgeons it is also called the *key of the Chopart joint* (clavis articulationis Choparti)*.*

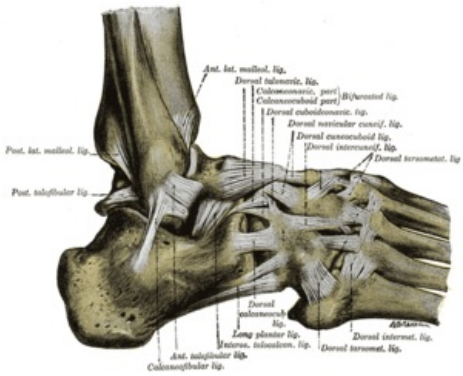

Ligaments – facies dorsalis

On the plantar side:

- ***lig. calcaneonaviculare plantare'*** *- the cartilaginous plate* fibrocartilago navicularis *is attached to it (it catches the head of the talus, supported from below by the tendon* m. tibialis posterior*);*
- ***lig. calcaneocuboideum plantare***;
- ***lig. plantare longum*** – a strong longitudinal ligament extending from the plantar surface of the calcaneus to the *articulationes tarsometatarsales*;
- ***lig. cuboideonaviculare dorsale et plantare*** - ligaments strengthening the transverse foot arch.

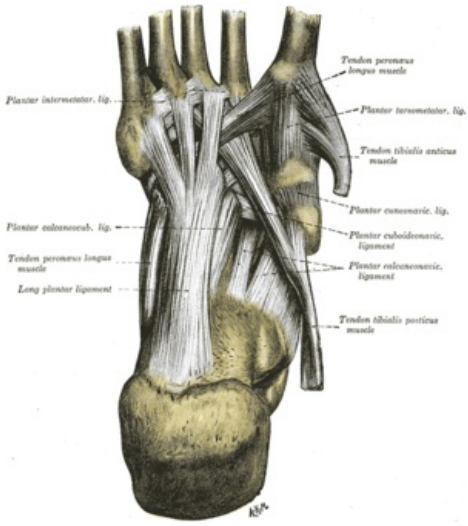

Ligaments – facies plantaris

Basic and intermediate position

Basic position - occupies the lower metatarsal joint while standing;

middle position - corresponds to the basic position.

Links

Related Articles

- Lower Extremity Connection
- Leg joints
- Ossa tarsi
- Lisfranc joint

References

- ČIHÁK, Radomír. *Anatomie 1.* 3. edition. Prague : Grada Publishing, a.s., 2011. 552 pp. vol. 1. ISBN 978-8-247-3817-8.