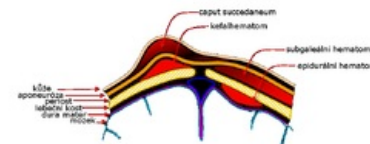


Cephalhematoma

Cephalhematoma is birth injury defined as a subperiosteal hemorrhage confined to the borders of the cranial bones, in most cases without accompanying skin changes. It is caused by the pressure of the birth canal during the pressure of the head during delivery and increases within a few hours after delivery. It is most often located above the parietal bone, less often above the occipital bone. Unlike *caput succedaneum* and subgaleal hemorrhage, it is bordered by cranial sutures. On palpation, it is a precisely defined, fluctuating or flexible structure above the skull bone. A risk factor for the development of cephalhematoma is instrumental delivery with forceps or vacuum extraction.



Scheme of head soft tissue injuries: birth tumor, cephalhematoma, subgaleal hematoma and epidural hematoma .

Cephalhematoma does not require treatment. First, during the first weeks, it calcifies from the edges and then ossifies. In the next period, the ossified cephalhematoma is gradually resorbed and the bone is remodeled to its original shape, without disturbing the symmetry of the calf.

In the case of larger cephalhematomas, it is initially recommended to monitor the blood count for the possibility of anemia and the bilirubin level for the possibility of progression icterus from extravasal breakdown of erythrocytes.^{[1][2][3][4][5]}

References

Related Articles

- Birth trauma
- Caput succedaneum

References

1. MATAS, M – CAKE, J – TOBRMANOVÁ, H. Natural course of spontaneous healing of cephalhematomas. *Pediatrics for practice* [online]. 2014, y. 15, vol. 1, p. 45-46, Available from <<https://www.pediatricpropraxi.cz/pdfs/ped/2014/01/12.pdf>>.
2. Dort J, et al. Neonatology. Prague: Karolinum, 2004.
3. Dort J, Dortová E, Jehlička P. Neonatology. 2nd ed. Prague: Karolinum 2013.
4. Gleason ChA, Devaskar S. Avery's Diseases of the Newborn. 9th ed. Philadelphia, Saunders 2011.
5. Lebl J, Janda J, Pohunek P, Stary J. Clinical pediatrics. Prague: Galén 2012.