

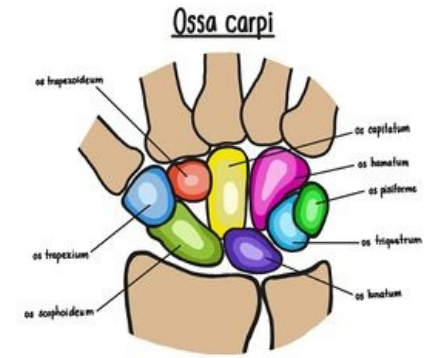# Carpal bones

The **carpal bones** (ossa carpi) consist of two rows of small bones, each row of four:

- **Proximal row** – (mediolaterally, ulnoradially) *os pisiforme*, *triquetrum*, *lunate*, *scaphoid*;
- **Distal row** – (mediolateral, ulnoradial) *os hamatum*, *capitulum*, *trapezoideum*, *trapezoid*.

The proximal series participates in radioulnar articulation. The distal ossa metacarpi (metacarpal bones ([https://www.wikilectures.eu/w/Metacarpal\\_bone](https://www.wikilectures.eu/w/Metacarpal_bone))) are attached.

The carpal bone forms the bony base of the carpal tunnel, through which the tendons of m. flexor digitorum superficialis et profundus and the median nerve, which is often oppressed here (carpal tunnel syndrome), pass.



Ossa carpi

## Proximal series

### Os pisiforme

Pisiform bone. It has both the shape and size of a pea grain. It develops as a sesame bone in the tendon of the ulnar flexor of the wrist.

### Os triquetrum

Triangular bone. It has the shape of an irregular tetrahedron.

### Os lunatum

Calendula bone. Its shape resembles a crescent.

### Os scaphoideum

Shuttle-shaped bone (not to be confused with *os naviculare* on tarsus). Its shape remotely resembles a boat, the depression is reversed medially. It is the largest bone of the proximal series. It bears *tuberculum ossis scaphoidei*. (unfortunately on the English version of the picture there is just mentioned error - naviculare x scaphoideum)

## Distal series

### Os hamatum

Hook-shaped bone. It has a triangular shape. Prominently from it stands out *hamulus ossis hamati* (hook).

### Os capitatum

Head bone. The largest carpal bone. The proximal part is called the *caput ossis capitati* and fits into the proximal series between the *os lunatum* and *os scaphoideum*.

### Os trapezoideum/Os multangulum minus

A small polygonal bone, or scarf-shaped. Its shape resembles the letter L (*shoe*), in the sagittal cross-section it has the shape of a pyramid turned by the base on the *dorsum manus*.

### Os trapezium/Os multangulum majus

Large bone polygonal. It has a similar shape to the *os trapezoideum*, but it is larger. Laterodorsally, there is a prominent saddle surface for articulation with the first (thumb) metacarpal bone.

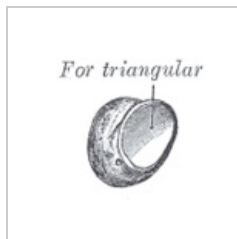
## ossification

Carpal ossifications ossify postnatally in the following order (approximate time of ossification in parentheses):

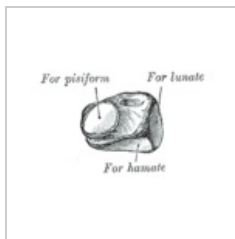
Os capitatum (2. m), hamatum (3. m), triquetrum (3. r), lunatum (4. r), scaphoideum (5. r), trapezium (5. r), *trapezoideum* (6. r), *pisiforme* (7.–13. r).

Ossification of carpal ossicles is a good indicator of a child's physical maturity.

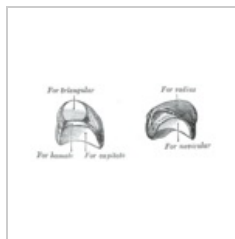
## Pictures



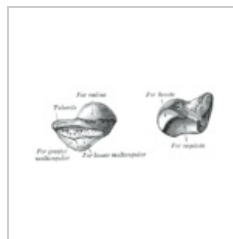
Os pisiforme  
sinistrum



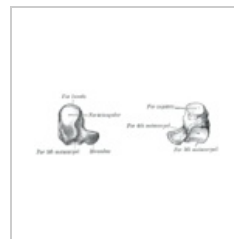
Os triquetrum  
sinistrum



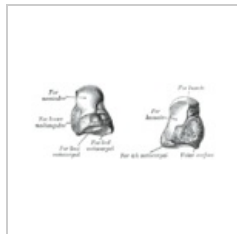
Os lunatum  
sinistrum



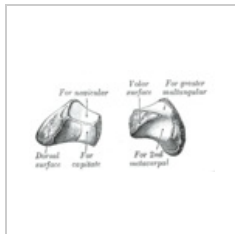
Os scaphoideum  
sinistrum



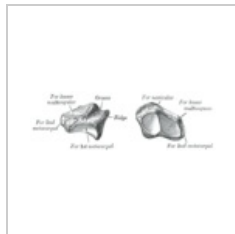
Os hamatum  
sinistrum



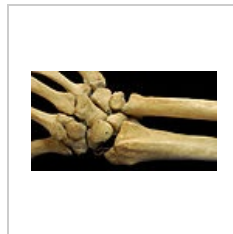Os capitatum  
sinistrum



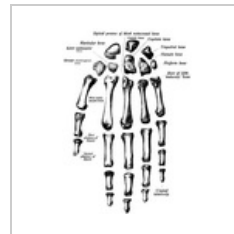
Os trapezoideum  
sinistrum



Os trapezium  
sinistrum



The relative  
position of the  
bones



Ossa manus

## Links

### Related Articles

- Bones of the upper limb

### Bibliography

- ČIHÁK, Radomír, et al. *Anatomie 1*. 1. edition. Praha : Grada Publishing, a.s., 2008. 516 pp. vol. 1. ISBN 80-7169-970-5.