

Carotid Triangle

English: *Carotid triangle*

Latin: *Trigonum caroticum*



Boundary

Carotid triangle is a space at the anterior portion of the neck. It is bound by the sternocleidomastoid muscle, by the superior belly of the omohyoid muscle and by the posterior belly of the digastric muscle with the stylohyoideus.

Content

This area contains common carotid artery with its branches: internal carotid artery and external carotid artery. External carotid artery then gives these branches:

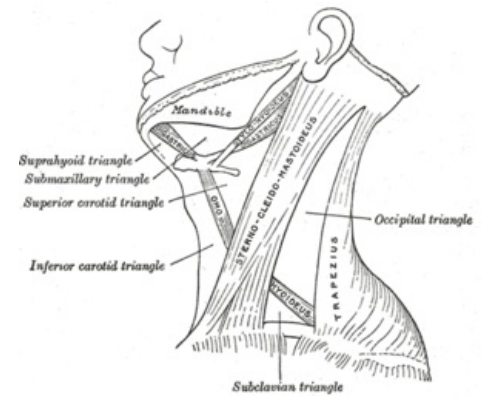
- superior thyroid artery (*arteria thyroidea superior*);
- lingual artery (*arteria lingualis*);
- facial artery (*arteria facialis*);
- occipital artery (*arteria occipitalis*);
- ascending pharyngeal artery (*arteria pharyngea ascendens*).

In the carotid triangle we can also see the hypoglossal nerve, which crosses the bifurcated carotid arteries, and accessory nerve. Behind the carotid arteries and internal jugular vein we can find the vagus nerve and much deeper the sympathetic trunk.

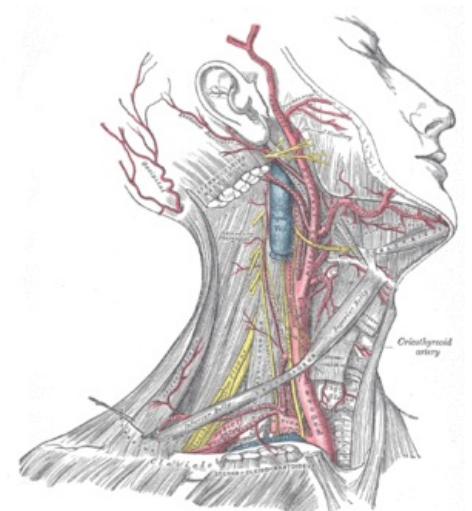
Links

Related articles

- Parapharyngeal Space



Carotid triangle



Content of the carotid triangle