

Cardiotocography

Cardiotocography (CTG)^[1] is a method of **fetal monitoring** using the simultaneous recording of fetal heart rate (cardiotachogram) and uterine contractions (tocogram). Modern devices enable a third signal modality in the form of recording fetal movements. The method is based on the fact that **hypoxic changes affect the hemodynamics of the fetus** and changes in the uteroplacental circulation will be manifested by a change in the frequency of fetal echoes^[1]. CTG diagnosis is in agreement with the diagnosis of hypoxia of a newborn after birth in 50-60%^[1]. The simultaneous use of CTG and STAN will reduce the incidence of metabolic acidosis by 60% and the number of operations for fetal distress by 25%^[1].

Physiology of uterine contractions

The basal tone of the uterus is around **10 mmHg**. At a pressure exceeding 20 mmHg, the venous flow through the uterus stops. At a pressure exceeding 60 mmHg, the arterial flow through the uterus stops (physiologically, the part of contraction lasting approx. 20 s). A healthy fetus has compensatory mechanisms (increase in flow, change in metabolism). However, if the refractory phases between contractions are not long enough, the contractions are arrhythmic, the contraction frequency is too high, the contractions are too long, or the basal tone itself is elevated above 20 mmHg, the fetal compensatory mechanisms are exhausted. Thus, an unaltered fetus gradually becomes an altered fetus and later an altered fetus incapable of compensation.

Tocogram

It is measured either by an external sensor, which mechanically measures the circumference of the abdomen, or by an internal one, which can be used to directly measure intrauterine pressure. Only the internal sensor can be accurately calibrated, but this is only used for research purposes. Only an external sensor is used clinically, whose absolute pressure values are indicative only.

The length, intensity and frequency of uterine contractions can be estimated on the tocogram. As a guideline, the **ideal contraction frequency is 4-6/10 min**. It is important for the evaluation of medium-term phenomena in the cardiotachogram.

Cardiotocogram

The recording method is Doppler ultrasonography. It is possible to use an external or internal probe (Hono's scalp electrode) which is used if the external one slips.

We distinguish between **long-term, medium-term and short-term phenomena**.

Long-term phenomena


It is about determining the basal rate, it is about a stable heart rate during a period of 5-10 minutes, from which medium- and short-term phenomena deviate.

Normal basal rate (**normocardia**) is 110-150/min. Mild tachycardia is a rate of 150-170/min, severe is over 170/min. At a frequency above 180/min, this is almost clear hypoxemia. Mild bradycardia is a basal rate of 100-110/min, severe bradycardia is below 100/min. and sometimes a very heavy rate below 90/min is distinguished, which - if it cannot be reversed otherwise - is an indication for acute or peracute termination of pregnancy.

Medium-term phenomena

We distinguish accelerations and decelerations. **Accelerations** are transient increases in frequency of 15/min from basal rate lasting longer than 15 s. **Sporadic accelerations** are a natural fetal catecholamine response to movements or to acoustic or mechanical stimuli. **Periodic accelerations** are accelerations occurring simultaneously with at least three successive contractions. Their shape is described (round, steep,...).

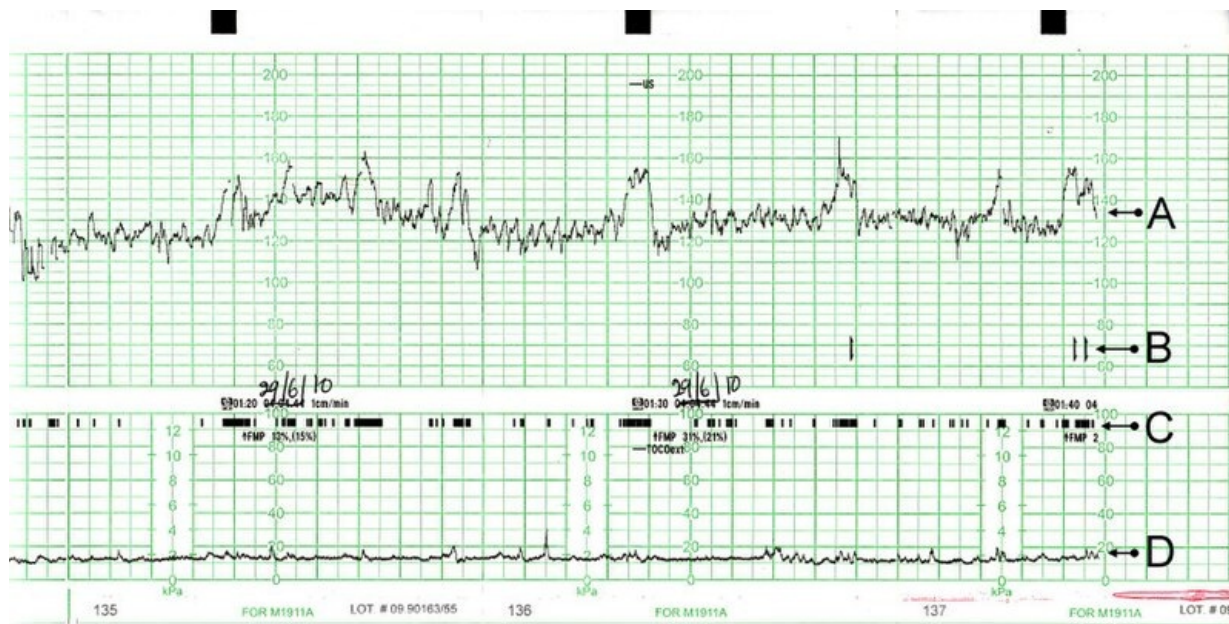
Decelerations are transient decreases in fetal heart rate with an amplitude exceeding 15/min. longer than 10 s. Sporadic decelerations (DIP 0) are not dependent on contractions, they are spiked, usually shorter than 30 s. They are usually a reaction to vagal irritation. If they are **prolonged**, it may be a decrease in uteroplacental flow as a result of aortocaval compression syndrome, large blood loss or shock. **Periodic decelerations** are dependent on uterine contractions and can be either **early (DIP 1), late (DIP 2), or variable**. Early periodic decelerations (DIP 1) have a peak directly opposite the peak of the uterine contraction in the tocogram. The cause may be compression of the fetal head or umbilical cord complication. If there are 1-3 of them within 20 minutes, the CTG record is evaluated as suspicious, if 4 or more, then as pathological. Late periodic decelerations (DIP 2) have a phase shift of 20-60 s relative to the peak of the contraction in the tocogram. They are the result of uteroplacental insufficiency, and when they occur, the CTG record is clearly pathological.



The principle of graphic representation of cardiotocography: the heart rate (A) is calculated from the fetal heart sound, which is determined using ultrasound, and the uterine contractions (B), which are measured using a pressure sensor.

Short-term phenomena

There are deviations of the fetal heart action from the basal rate of less than 15 s. With an amplitude of 10-25/min, they are in the so-called **undulatory zone**. The amplitude of 5-10/min is a **narrowed undulatory zone**, which is caused by the depression of the fetal circulation, mostly by fetal sleep or pharmacologically induced depression. An amplitude of less than 5/min is referred to as a **silent zone**. It is caused by fetal hypoxia. Termination of pregnancy is indicated after exclusion of sleep and pharmacological fetal depression. Deflections with an amplitude higher than 25/min are referred to as a **saltator zone**. They are mostly caused by the umbilical cord complication, which the fetus tries to compensate for. Variable short-term phenomena with an amplitude of 5-15/min changing their amplitude in a time period longer than 20 min according to the course of the sinusoid are referred to as sinusoidal oscillations. They are a sign of chronic hypoxia of the fetus, often caused by anemia (Rh incompatibility,...).



Resting CTG recording of a barren woman. A: Voice fruits B: Fetal movements registered by the mother (she presses the button when she feels movement) C: Real fetal movements D: Uterine activity

Assessment

The evaluation of the CTG record is carried out by the obstetrician and can be threefold (marks 1, 2 and 3, or the letters F, S and P):

1. physiological record (**F**)
2. suspicious record (**S**),
3. pathological record (**P**).

Methods of monitoring

CTG is performed both before and during labor. It can be monitored either **intermittently or continuously**. Indications for continuous recording are: suspicious or pathological NST, meconium turbidity of the amniotic fluid, prematurity, IUGR, maternal hypertension, previous cesarean delivery, epidural analgesia (due to a certain risk of maternal hypotension and subsequent fetal hypoxia), basal frequency abnormality in CTG, oligohydramnios, postmaturity, suspicious CTG recording, application of oxytocin or prostaglandins, internal diseases of the mother (diabetes mellitus,...), infection, chorioamniitis, during the 2nd stage of labor^[1].

Links

Related articles

- Fetal hypoxia
- Intrapartum fetal monitoring
- Fetal pulse oximetry
- Fetal ECG

Reference

1. KREJČÍ, Vratislav. *Kardiotokografie, poruchy děložní činnosti, hypoxie plodu* [lecture for subject Gynekologie a porodnictví předstátnicová stáž, specialization Všeobecné lékařství, 1. lékařská fakulta Univerzita Karlova v Praze]. Praha. 17.2.2013.

Recommended literature

- MĚCHUROVÁ, Alena. *Kardiotokografie : minimum pro praxi*. 1. edition. Praha : Maxdorf, 2012. 183 pp. ISBN 978-80-7345-274-2.