

# Cardiomyopathies

**Cardiomyopathies** (CMP) are a group of diseases whose dominant feature is the involvement of the heart muscle itself (myocardium). These are often diagnosed by exclusion when other possible causes of myocardial involvement are ruled out (typically Ischemic heart disease, Valvular defects, Arterial hypertension).

## Classification of Cardiomyopathies

According to the European Society of Cardiology, cardiomyopathies are divided on the basis of various morphological and functional features into five basic groups - **hypertrophic, dilated, restrictive, arrhythmogenic and unclassified cardiomyopathy**' (e.g. noncompact cardiomyopathy and tako-tsubo cardiomyopathy). Furthermore, these categories can be broken down in even more detail according to whether they are on a *genetic basis* (familial) or not, or whether or not they are **idiopathic**.<sup>[1]</sup> **Classification is also possible on the basis of etiology**, eg anthracycline, alcoholic, inflammatory cardiomyopathy. The situation is complicated by the fact that individual agents, including mutations, can lead to the development of different types of cardiomyopathies, e.g. sarcoidosis can take on the appearance of dilated or restrictive cardiomyopathy.

## Dilated cardiomyopathy

According to the European Society of Cardiology, **dilated cardiomyopathy is defined as** "the presence of dilation and systolic dysfunction of the left or both heart chambers in the absence of abnormal filling conditions (arterial hypertension, valvular defects) or coronary artery involvement sufficient to cause global systolic dysfunction."<sup>[2]</sup> In other words, there is a *dilation* of the left heart chamber, possibly also of other heart compartments, and a *systolic dysfunction* of the chamber, which cannot be explained by other possible precipitating causes. Dilated cardiomyopathy is together with Hypertrophic cardiomyopathy one of the **most frequently diagnosed** cardiomyopathies.<sup>[2][3]</sup> Its etiopathogenesis is extremely broad. Etiology, or the phenotype of dilated cardiomyopathy includes **genetic causes**, infectious or post-infectious involvement (*inflammatory cardiomyopathy* after previous Myocarditis), endocrine causes, Gestational cardiomyopathy, cardiotoxic damage to the myocardium (antitumor treatment, alcohol, cocaine), neuromuscular and autoimmune disorders.<sup>[2][4][5]</sup> It is mainly manifested by *left-sided heart failure*, arrhythmias and thromboembolic complications. Diagnosis is based on **non-invasive** (ECG, echocardiography, magnetic resonance) and in some cases also *invasive* examination methods (e.g., endomyocardial biopsy).<sup>[3][5][6]</sup> Due to the wide etiology, the treatment of dilated cardiomyopathy is also very diverse. Both standard heart failure treatment and, in indicated cases, resynchronization treatment of heart failure, ablation techniques, or heart transplantation are applied. Specific treatment is also not a simple issue, however, it is already available in many cases.<sup>[3][4]</sup>

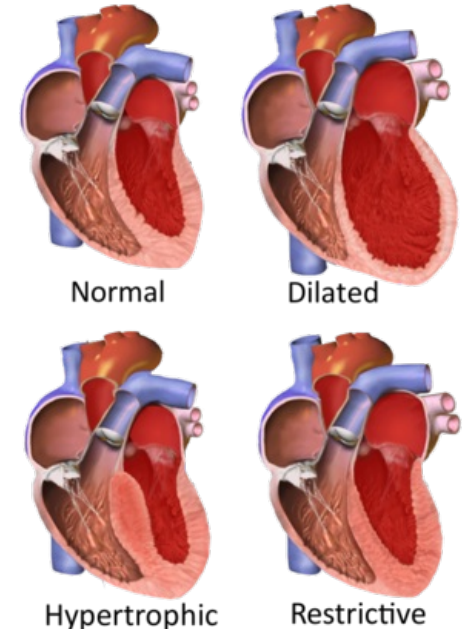
 For more information see *Dilated cardiomyopathy*.

## Hypertrophic Cardiomyopathy

**Hypertrophic cardiomyopathy** is one of the most common types of cardiomyopathy with a frequency of 1:500 and also one of the *most frequent causes of sudden death in young individuals and athletes*. It is characterized by thickening (hypertrophy) of the myocardium without the presence of left ventricular dilatation, while excluding other pathologies that could explain the myocardial hypertrophy (e.g. arterial hypertension, aortic valve stenosis, ischemic heart disease, etc.).

The most common cause of hypertrophic cardiomyopathy is **mutation of genes encoding sarcomeric components of cardiomyocytes**. However, the situation is complicated by the fact that a specific mutation is identified in only about 50% of patients, and also by the occurrence of mutations in which their association with hypertrophic cardiomyopathy is still unclear (variation of unclear significance). In some cases, hypertrophic cardiomyopathy also occurs in ``metabolic and neuromuscular disorders (*Fabry Disease, Friedreich's ataxia*).

The clinical picture is diverse, including asymptomatic cases and patients in whom the first manifestation is **malignant arrhythmia or sudden cardiac death, which is also one of the main dangers of this disease**. **Hypertrophic cardiomyopathy is accompanied by diastolic dysfunction (poor relaxation of the hypertrophic myocardium) and, in the vast majority of cases, the hyperdynamic function of the left ventricle with its intact systolic function. Due to the genetic basis of the disease, whose inheritance is autosomal dominant**' with high penetration, other family members are also examined as part of the cascade screening.



Types of Cardiomyopathies

The diagnostic process includes both a basic ECG and echocardiographic examination, as well as other imaging techniques such as magnetic resonance of the heart, computed tomography or coronary angiography with the aim of showing hypertrophy and other structural or functional changes of the myocardium and excluding other diseases that could explain the patient's condition. The primary goal of therapy is **the prevention of sudden death and the treatment of symptoms**'. Therefore, timely stratification of the risk of sudden death is absolutely essential. Treatment consists of regimen measures, pharmacological treatment, anticoagulation and interventional therapy for atrial fibrillation, ICD implantation when the indication criteria are met, and in selected patients, alcohol ablation of the septum or septal myectomy.

 For more information see *Hypertrophic cardiomyopathy*.

## Restricted Cardiomyopathy

**Restrictive (restrictive) cardiomyopathy** is a rare type of cardiomyopathy characterized by reduced compliance or increased stiffness of the myocardium of the ventricles. This leads to the development of ``severe diastolic dysfunction, *primarily of the left ventricle, without the presence of dilatation, but with the presence of severe dilatation of the heart atria. In the later stages of the disease, the systolic function of the ventricles may also be affected. Signs of chronic heart failure and conduction heart disorders predominate in the clinical picture. The etiology of restrictive cardiomyopathy is very diverse and includes both genetic mutations and some infiltrative, spasmodic, and inflammatory diseases (e.g., Hemochromatosis and endomyocardial fibrosis). In the differential diagnosis, it is necessary to distinguish restrictive cardiomyopathy from restrictive pericarditis.*

The diagnosis of sarcoidosis is suspect in patients with **AV blockades of a higher degree. Magnetic resonance imaging of the heart and PET have an important position. Magnetic resonance imaging and iron metabolism testing are also used for hemochromatosis. In ``sarcoidosis, the main treatment option in indicated cases is immunosuppressive therapy, or primary prevention of arrhythmias in the form of ICD implantation.**

 For more information see *Restrictive cardiomyopathy*.

## Arrhythmogenic Cardiomyopathy

**Arrhythmogenic cardiomyopathy** is a genetically determined cardiomyopathy that is characterized by *fibrolipomatous replacement of the myocardium*. Mutations occur mainly in genes encoding intercalary disc proteins, as a result of which they are **disrupted intercellular junctions**. The division of cardiomyocytes is also supported by increased physical exertion in patients. The type of inheritance is usually autosomal dominant. The disease is mainly manifested by ventricular tachycardia, systolic dysfunction of the right/left or both ventricles and in some cases even sudden cardiac death, which can also be the first manifestation of the disease. At the same time, arrhythmogenic cardiomyopathy is **one of the most common causes of sudden death in young individuals**'. Previously, only arrhythmogenic cardiomyopathy (dysplasia) of the right ventricle was defined. However, the left ventricle can also be affected in isolation. According to the latest recommendations, it is, therefore, preferable to use the more general designation "arrhythmogenic cardiomyopathy".

The diagnosis of arrhythmogenic cardiomyopathy is a very complex process. It is based primarily on a positive family history, deviations on the ECG and detected changes in the structure and function of the heart chambers (mainly with the use of echocardiography and magnetic resonance of the heart). Furthermore, histopathological changes of the myocardium are examined. Part of the diagnosis is genetic examination of mutations associated with arrhythmogenic cardiomyopathy, including "cascade screening" of close relatives. Treatment focuses on limiting physical activities, preventing malignant arrhythmias and sudden death, and treating heart failure. There is no causal treatment yet.

 For more information see *Arrhythmogenic cardiomyopathy*.

## Cardiac Sarcoidosis

'*Sarcoidosis of the heart is a granulomatous inflammatory disease of the myocardium. It can appear together with other extracardiac lesions or alone. Sarcoidosis itself is a multisystem disease of unknown cause. It usually affects individuals between the ages of 25 and 60. Granulomatous inflammation is most often localized in the lungs. The eyes, liver, GIT, skin or nervous tissue can also be affected. Cardiac sarcoidosis is manifested by 'AV conduction disorders and supraventricular and ventricular arrhythmias. These are the main danger of the disease. We also observe the development of heart failure. The presence of cardiac sarcoidosis and the degree of cardiac dysfunction are important predictors of patient prognosis.*

ECG, Holter monitoring (intermittent occurrence of arrhythmias) and echocardiography are used in the first line of diagnosis. These examinations complement **18-FDG PET/CT" (positron emission tomography using 18-fluorodeoxyglucose) and MRI**. Treatment is aimed at suppressing inflammatory and fibrotic activity with immunosuppressive therapy, treating cardiac dysfunction and preventing malignant arrhythmias.

 For more information see *Cardiac Sarcoidosis*.

## Cardiac Amyloidosis

**Cardiac amyloidosis** is an infiltrative disease characterized by **deposition of amyloids** in the extracellular spaces of the myocardium. It can be part of systemic amyloid disease or develop independently. According to the types of amyloid precursor proteins, amyloidoses are classified into several types. The most common types are **AL** (from immunoglobulin light chains) and **TTR** (transthyretin) amyloidosis. The clinical picture is diverse and depends on which organ is affected. In the case of the heart, these are mainly symptoms of unilateral or even biventricular *heart failure*.

The diagnosis of amyloidosis depends on the clinical picture, analysis of blood and biopsy samples, and typical signs on the ECG and imaging methods. Examination of the *serum level of free kappa or lambda light chain* is important in the case of AL amyloidosis. Definitive diagnosis is based only on the evaluation of the *biopsy sample* of the affected organ.

Treatment is aimed both at treating heart failure and at the very cause of amyloid formation. '*Specific treatment* of AL amyloidosis is targeted at plasma cells, including the use of chemotherapeutic drugs and specific monoclonal antibodies. Sometimes patients are indicated for bone marrow transplant. TTR amyloidosis currently has a specific treatment in the form of a transthyretin tetramer stabilizer (*Tafamidis*).

 For more information see *Cardiac Amyloidosis*.

## Tako-tsubocardiomyopathy

*Tako-tsubo cardiomyopathy* (sometimes called apical ballooning cardiomyopathy, broken heart syndrome, stress cardiomyopathy) is a rare disease of unclear etiology. Today, the most accepted theory is about the myocardial stunning by a high concentration of **'catecholamines'** in the circulation. Catecholamines are directly toxic to the myocardium and secondarily cause transient microvascular dysfunction. The disease *mimics acute coronary syndrome* and is often manifested by acute heart failure.

A typical image on imaging methods (including ventriculography) is **reduced contractility of the apical segments of the left ventricle'**, which is compensated by **increased contractility of the basal segments**. Although the disability is mostly reversible, serious and life-threatening complications can also occur.

In the acute phase, it is necessary to repeatedly monitor the patient's ECG and echocardiographic parameters. Treatment is individual, caution is required when using inotropic agents. ACE-inhibitors, diuretics and beta-blockers are used in the therapy of heart failure, which also have a certain anti-arrhythmic effect and can improve the obstruction of the outflow tract of the left ventricle.

 For more information see *Tako-tsubo cardiomyopathy*.

## Gestational Cardiomyopathy

**Pregnancy cardiomyopathy** is classified among idiopathic cardiomyopathies. The pathophysiological mechanisms have not yet been fully elucidated. Genetic, nutritional, hormonal, metabolic and other factors contribute to the manifestation of the disease, and above all their mutual combination. Diagnosis usually takes place by exclusion.

In order for this diagnosis to be established, three basic diagnostic criteria must be met - the presence of **'acute heart failure' with a reduced ejection fraction, the manifestation of difficulties in the peripartum period' or in a few months after childbirth (eventually abortion), and exclusion of other possible causes** of heart failure. The clinical picture of pregnancy cardiomyopathy is diverse. **Pharmacological intervention is limited, among other things, with regard to the health of the fetus. This is a potentially life-threatening disease that requires early diagnosis.**

'*Pregnant patients are contraindicated ACE-inhibitors, sartans, aldosterone receptor blockers, ivabradine and warfarin*. Beta blockers, nitrates and diuretics are mainly used to treat heart failure in pregnant patients. There is an increased risk and occurrence of thromboembolic complications in patients with pregnancy cardiomyopathy. The situation with pharmacological treatment changes as soon as the patient gives birth. A promising drug is the **agonist dopamine D2 receptors bromocriptine'**.

 For more information see *Gestational Cardiomyopathy*.

## Noncompact Myocardium

In the case of non-compact myocardium, we assume an embryonic disorder of the development of the myocardium. There is a *violated physiological reconstruction of the spongy myocardium* - the so-called solidification (it takes place prenatally from the 8th week). Here we find multiple trabeculae protruding into the interior of the ventricle (spongy myocardium). Complications are heart failure, malignant ventricular tachycardia, thromboembolic events in early childhood.

## Division according to WHO

- **primary CMP** - myocardial disease of unknown cause;
- **secondary myocardial infarction** (specific myocardial diseases) - myocardial diseases for which the cause is known.

# Links

## External Links

- Kardiomyopatie (TECHmed) (<https://www.techmed.sk/dilatacna-kardiomyopatia/>)

## Reference

1. ELLIOTT, P. – ANDERSSON, B. – ARBUSTINI, E.. Classification of the cardiomyopathies: a position statement from the european society of cardiology working group on myocardial and pericardial diseases. *European Heart Journal*. 2007, y. 2, vol. 29, p. 270-276, ISSN 0195-668X. DOI: 10.1093/eurheartj/ehm342 (<http://dx.doi.org/10.1093%2Feurheartj%2Fehm342>).
2. PINTO, Yigal M. – ELLIOTT, Perry M. – ARBUSTINI, Eloisa. Proposal for a revised definition of dilated cardiomyopathy, hypokinetic non-dilated cardiomyopathy, and its implications for clinical practice: a position statement of the ESC working group on myocardial and pericardial diseases. *European Heart Journal*. 2016, y. 23, vol. 37, p. 1850-1858, ISSN 0195-668X. DOI: 10.1093/eurheartj/ehv727 (<http://dx.doi.org/10.1093%2Feurheartj%2Fehv727>).
3. PALEČEK, Tomáš, et al. *Onemocnění myokardu* [online]. [cit. 2023-05-14]. <<http://ecardio.cz/Article/Index2.aspx?ArticleId=91#a1738>>.
4. SEFEROVIĆ, Petar M. – POLOVINA, Marija – BAUERSACHS, Johann. Heart failure in cardiomyopathies: a position paper from the Heart Failure Association of the European Society of Cardiology. *European Journal of Heart Failure*. 2019, y. 5, vol. 21, p. 553-576, ISSN 1388-9842. DOI: 10.1002/ejhf.1461 (<http://dx.doi.org/10.1002%2Fejhf.1461>).
5. ZEMÁNEK, David. *Dilatační kardiomyopatie* [online]. [cit. 2023-05-14]. <<https://www.kardio-cz.cz/data/clanek/423/dokumenty/465-zemanek-dilatacnikmp.pdf>>.
6. MANN, Douglas L, et al. *Braunwald's Heart Disease : A Textbook of Cardiovascular Medicine*. 10th Edition edition. 2015. ISBN 978-0-323-29429-4.