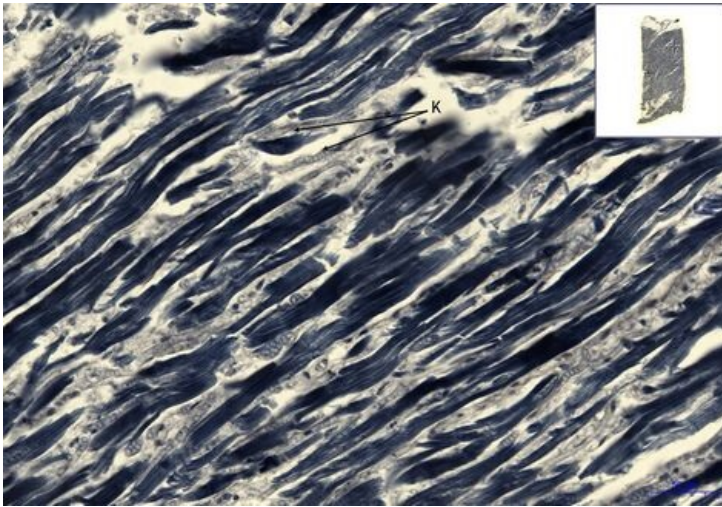


# Cardiac muscle - HIH

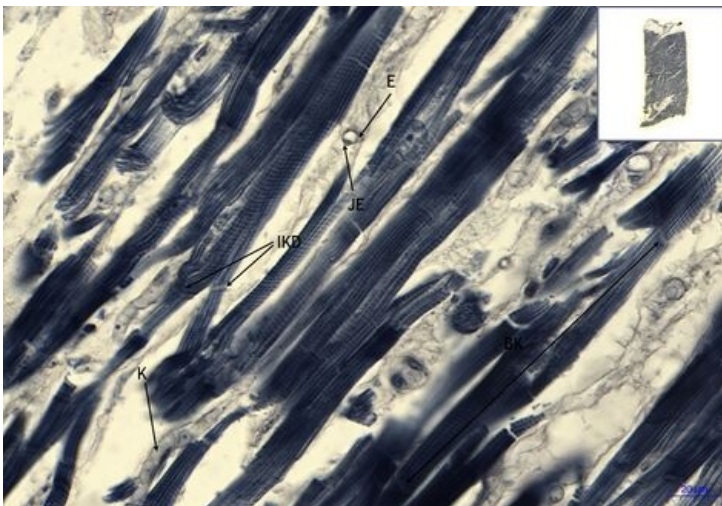
## Myokard, HIH 20x



### Cardiac muscle - longitudinal:

- **K** - capillary

## Myokard, HIH 40x



### Cardiac muscle - longitudinal:

- **E** - endothelium
- **JE** - endothelium nucleus
- **IKD** - intercalated disc
- **BK** - cardiomyocyte
- **K** - capillary