

Carcinoid

Carcinoid is a tumor that comes from cells of the **DNES (diffuse neuroendocrine system)**, formerly called **APUD-system** (amine precursors uptake and decarboxylation system). It is a relatively rare tumor, but its incidence is rising.

DNES cells are:

- **Enteroendocrine cells** (Kulchitsky cells in the digestive tract epithelium) in the pancreas, bronchial epithelium, gallbladder and bile ducts, salivary glands and lacrimal glands, epithelium of the nasal mucosa, epithelium of the urogenital system, in the macula densa of nephron, in mammary glands, and in the stratum basale of the epidermis.

Macroscopy

A small solid nodule in the submucosa that can extend to the muscle, that is yellowish or ocher in color upon incision. The mucosa above it is intact or exulcerated.

Microscopy

There are two types of carcinoids:

1. **Oberndorfer's argentaffin carcinoid** - from enteroendocrine cells (GIT) - solid trabecular or alveolar structure, histamine and serotonin production, a carcinoid with mucus production is rare (so-called carcinoid from Goblet cells);
2. **carcinoid from other DNES cells** - tubular, trabecular, cribriform structure, production of agents according to the localization.

The carcinoid consists of cells with a light, finely granulated cytoplasm (argentaffinic or argyrophilic granule, chromaffinic, positive diazo reaction), with round or oval nuclei, low mitotic activity.

Biological activity

- Carcinoid cells produce both **biogenic amines** (especially serotonin - a powerful constrictor of gastrointestinal smooth muscles and bronchi - such cells are argentaffinic and chromaffinic), as well as polypeptide hormones.
- Serotonin is degraded in the liver, hyperserotonemia can occur only in liver metastases, when it is released directly into the liver veins without degradation. The clinical manifestation of the carcinoid is the so-called **carcinoid syndrome**.

Clinical picture

They may have very non-specific symptoms. The main manifestations are abdominal pain, abdominal discomfort, and weight loss. It can also manifest itself as bleeding into the GIT or just occult blood loss. If the agents that carcinoids produce (mainly serotonin, histamine, norepinephrine and others) get into the blood, it conditions the development of carcinoid syndrome.

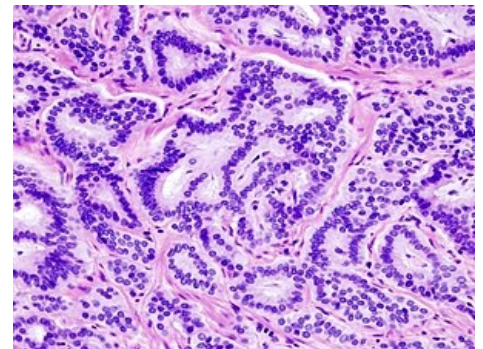
Carcinoid syndrome

Clinical manifestations of carcinoid include:

1. **flush** - paroxysmal redness of the face, neck and upper chest (vasodilation);
2. **diarrhea** - increased intestinal motility;
3. **asthma attacks** - bronchospasms;
4. **thickening of the tricuspid and pulmonary valve** - the effect of serotonin directly on the endocardium, the only case where the valves of the right heart are primarily affected. Unlike rheumatic endocarditis there are no calcifications, and there is a combined defect (tricuspid - *mainly insufficiency*, pulmonary - *mainly stenosis*) - hypertrophy and dilatation of the right ventricle.
5. **muscle wasting**

Localization

In the GIT, the carcinoid is most often located in the appendix and ileum, and less commonly in the rectum, stomach and colon. It is considered a potentially malignant tumor (appearance of a benign tumor, but may metastasize), **practically does not metastasize in the rectum**, in the stomach over 1 cm in size, in the



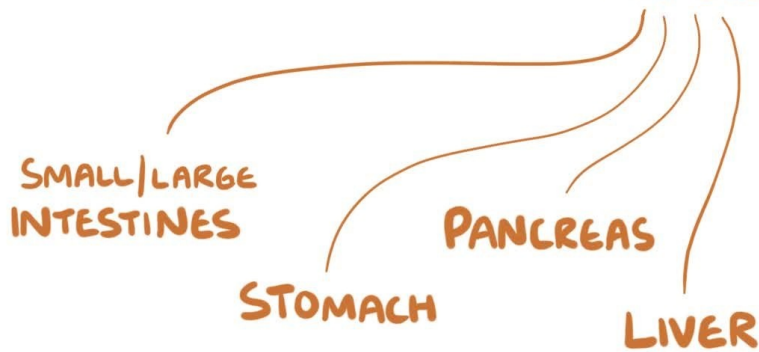
Intestinal carcinoid, stained by hematoxylin-eosin - round to oval nuclei are typical, occupying most of the cell, the proportion of cytoplasm is smaller

appendix over 2 cm, **metastasizes to regional lymph nodes and to the liver.**

Summary video

CARCINOID TUMORS

- * SLOW GROWING
- * SOME METASTASIZE
- * COMMON PRIMARY SITES



Links

Related articles

- Intestinal tumors
- Bronchogenic carcinoma

Reference

- PASTOR, Jan. *Langenbeck's medical web page* [online]. ©2010. [cit. 02-06-2010]. <<http://langenbeck.webs.com>>.