

Caput succedaneum

Caput succedaneum, or **birth tumor**, is a diffuse infiltration of the tissues on the leading part of the head during childbirth. The swelling is localized between the galea aponeurotica and the skin, on which we can observe petechiae/small hematomas. Unlike a cephalhematoma, the swelling overlaps the skull sutures. It does not require treatment and disappears spontaneously within a few days.^[1]

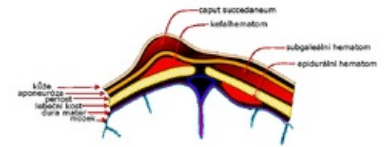
Sources

Related articles

- Birth trauma
- Kefalhematom

Reference

1. HAVRÁNEK, J.: *Traumatický novorozenec*.



Schematic of head soft tissue injuries: birth tumor, cephalhematoma, subgaleal hematoma, and epidural hematoma