

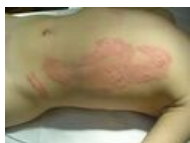Burn necrosis

Burn necrosis is a layer of dead tissue that has no hope of recovery and must therefore be removed as soon as possible. Burn IIb and III. St. it still has a so-called transition zone (intermediate zone or stasis zone) under the layer of necrosis. These changes are caused by post-traumatic microcirculation disorders under the necrosis.

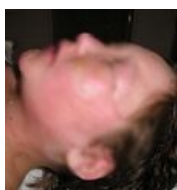
Development of necrosis

Every burn, whether superficial or deep, is associated with the development of local edema . It is caused by released mediators (TNF alpha , IL-1,2), paresis of vegetative nerve braids of capillaries, change in permeability of capillary walls and changes in interstitial oncotic and osmotic pressure in the burn area. Edema-encrusted microcirculation results in tissue hypoxia, intravascular microthrombotization, and progressive deepening of the burn. The gradual death of tissues after thermal damage, even with adequate treatment, comes to an end approximately on the 3rd day after the injury. Weakened tissues are prone to infectious complications and can be dangerous for the patient if they are larger. Therefore, the recommended period for the removal of non-vital tissues is scheduled to 3-5. days since the injury.

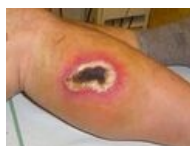In the case of an extensive burn, generalized edema occurs, which, if not adequately treated, can endanger the patient's life as a result of the enormous displacement of fluids from the circulation. The burned area practically never has a uniform depth throughout its entire extent. This is especially true for extensive injuries, where it is often a combination of superficial and deeper burns, and when describing and evaluating individual areas, it is necessary to differentiate between the differences in damage. The basic structure is a bowl-shaped lesion, where the central parts are deeper and the peripheral parts are more superficial. Very descriptively, the center is a III burn. degrees, surrounded concentrically by IIb, IIa and I. degree burns. Typical examples are contact burns after touching the skin with a hot metal surface, or burns caused by a concentric flame during an autogen burn, etc.



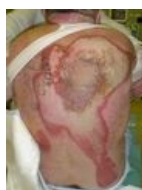Collateral swelling on the trunk after scald IIa degree



Massive facial swelling after a flame burn



Representation of the concentric arrangement of the surface burned by autogen



Back burn from liquid metal splash in a foundry. The center is the deepest, in the edges it passes into more superficial damage and smoothly into healthy tissue.

Links

related articles

- Surgical treatment of burns
- Burns

Source

- KÖNIGOVÁ, Radana – BLÁHA, Josef, et al. *Comprehensive treatment of burn trauma*. 1. edition. Prague : Karolinum, 2010. ISBN 978-80-246-1670-4.