

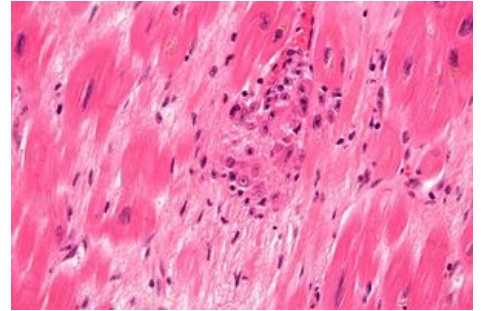
Aschoff cells

Aschoff cells are histiocytic elements found around fibrinoid necrosis of Aschoff nodules in rheumatic endocarditis. Compared to Anichkov's cells, they are larger, can be multinucleated (1, 2 or 3 nuclei) and have basophilic cytoplasm.

Links

References

- POVYŠIL, Ctibor, Ivo ŠTEINER and Pavel DUŠEK, et al. *Special pathology*. 2nd edition. Prague: Galén, 2007. 430 pp. ISBN 978-807262-494-2 .
- VOKURKA, Martin and Jan HUGO, et al. *The Great Medical Dictionary*. 5th edition. Prague: Maxdorf, 0000. 1008 pp. Jessenius; ISBN 80-7345-058-5 .



Aschoff cells