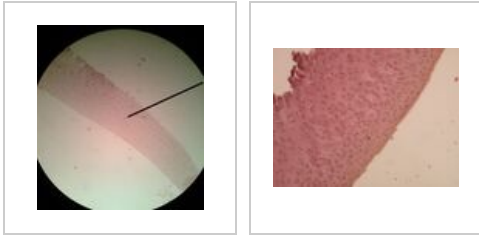


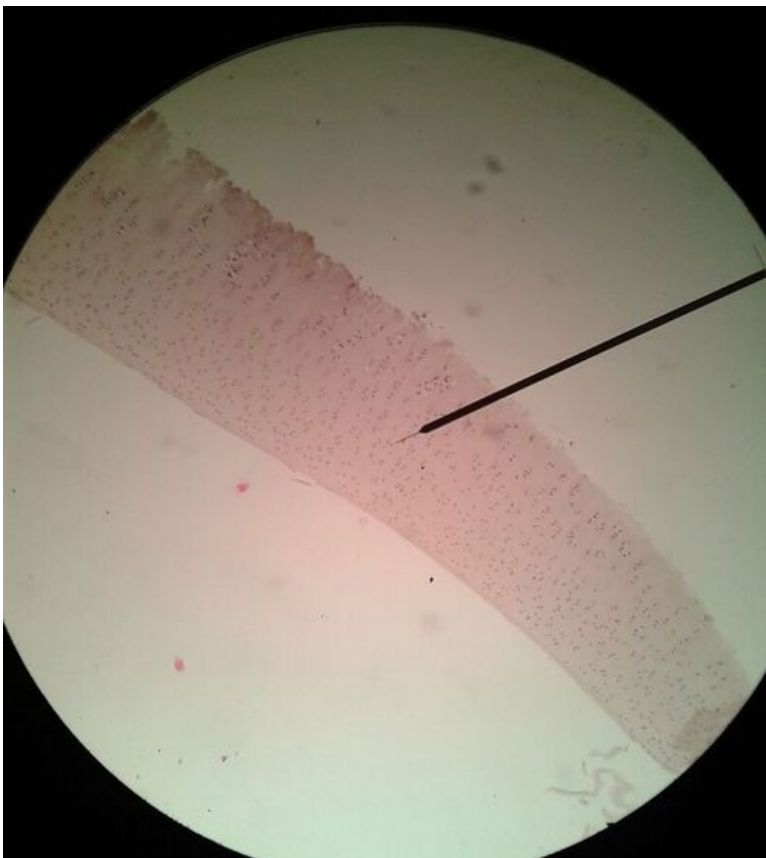
Articular cartilage (slide)

Articular cartilage

Přehled



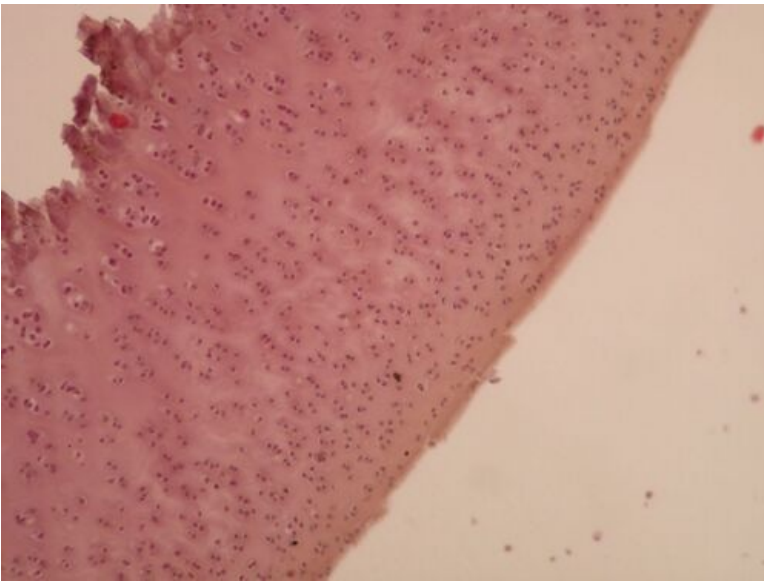
Slide 1



Name:

Description:

Slide 2



Name:

Description:

Connective tissue

Mesenchyme (slide)

Umbilical cord (slide)

Aorta (slide)

Brown adipose tissue (slide)

White adipose tissue (slide)

Tendon (slide)

Articular cartilage (slide)

Epiglottis (slide)

Intramembranous ossification (slide)

Endochondral ossification (slide)

Lamellar bone (slide)

Links

Module Cell basis of medicine (3. LF)

Study materials for this slide