

Arteria radialis

'*Arteria radialis*' descends from the division of *arteria brachialis* in the elbow landscape along the radial side. On the wrist, between *musculus brachioradialis* and *musculus flexor carpi radialis* its pulse is palpable. [1] We can also find it in *foveola radialis*. After crossing *ossa carpi*, it runs on the dorsal part of the hand, where between the heads of *m. interosseus dorsalis primus* enters *Guiot's space* and forms *arcus palmaris profundus*. [2]

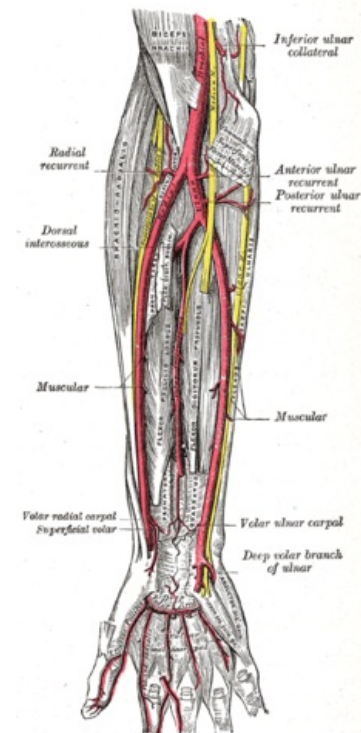
It branches into *r. palmaris superficialis* that supplies '*arcus palmaris superficialis*', it has also branches for *rete carpi palmare* and *dorsale* and *arteria princeps pollicis*. It supplies the muscles of the anterior and lateral groups and the skin in the lateral half of the forearm. *Arteria radialis* also participates in the supply of the palm, the back of the hand and fingers. ^[1]

Links

Reference

1. ČIHÁK, Radomír. *Anatomy 3*. 2. edition. Prague : Grada Publishing, 2004. 692 pp. ISBN 978-80-247-1132-4.
2. HOLEK, Martin. *Anatomy of limbs for winter autopsy room [electronic resource] : (unsaleable script for first-year students of the 3rd Faculty of Medicine, Charles University)*. 1. edition. Prague : Charles University, 3. Faculty of Medicine, 2009. ISBN 978-80-254-3223-5.

Template:Navbox - upper limb arteries



12.2.09.027%20Entity%20TA98%20EN.htm
A 12.2.09.027 (<http://www.unifr.ch/ifaa/Public/EntryPage/TA98%20Tree/Entity%20TA98%20EN/>)

a. nbps; recurrens radialis, a. nbps;
nutricia radii, r. nbps; carpalis palmaris,
'r. nbps; palmaris superficialis', r. nbps;
carpalis dorsalis,' a. nbps; princeps
pollicis', a. nbps; radialis indicis, '*arcus*
palmaris profundus'