


Alport's syndrome

This article has been translated from WikiSkripta; the **formatting** needs to be checked.

Non-Proliferative glomerulonephritis (Nephrotic syndrome/Glomerulonephrosis):



Template:Infobox - genetic disease **Alport's syndrome** is an inherited disease in which the function of the kidney [[glomeruli]] is affected. Dysfunction consists in thinning of the basement membranes of glomeruli due to poor synthesis of collagen IV α -chains .

Causes

This syndrome is most often caused by a mutation in the gene for the α_5 chain of collagen IV (most often a mutation in the gene COL4A5 on the X chromosome), less often by a mutation in the gene for the α_3 or α_4 chain of collagen IV. Heredity can be X-linked, autosomal recessive or autosomal dominant. The mutation causes the formation of defective chains, which are subsequently degraded, the $\alpha_{3,4,5}$ complex is not formed in the basement membrane. For this reason, the basement membrane is more prone to proteolysis, which manifests itself in morphological changes - the fiberization of the basement membrane and the alternation of its widened and narrowed sections.

Mutated genes in Alport syndrome				
Gene	Locus	Protein	Heredity	% of cases
COL4A5	Xq22.3	chain α_5 of collagen IV	X-linked	80 %
COL4A3	2q36-q37	α_3 chain of collagen IV	autosomal recessive / dominant	15 % in AR, 5 % in AD
COL4A4	2q36-q37	α_4 chain of collagen IV	autosomal recessive / dominant	15 % in AR, 5 % in AD

Consequences

Classical Alport syndrome is characterized by impaired renal function (manifested as nephritic or nephrotic syndrome). In fully developed Alport syndrome (otherwise also **progressive hereditary nephritis**), bilateral hearing and eye disorders are added.

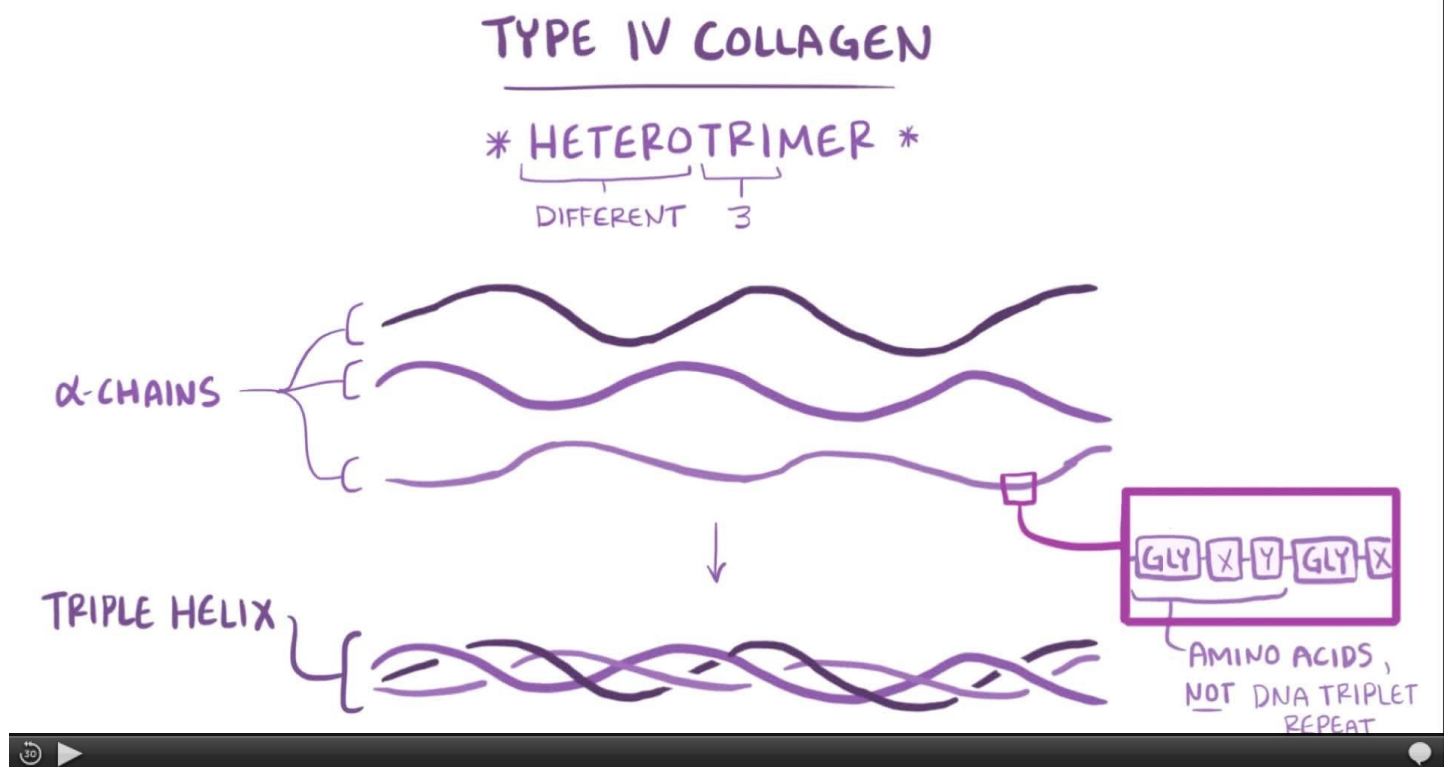
Eye disorders include anterior lenticon(practically pathognomic), maculopathy, posterior polymorphic corneal dystrophy, and corneal erosion.

Collagen IV also occurs in the basal layer of the epidermis. Here, this deficiency does not lead to any problems and can be used to make a diagnosis.

The so-called **thin basal membrane syndrome** is called a milder form of X-linked Alport syndrome, a mutation in the COL4A3 (<http://omim.org/entry/120070>) or COL4A4 (<http://omim.org/entry/120131>) gene. This syndrome can also be described for its morphology as non-progressive hereditary nephritis or for its manifestation also as so-called benign familial hematuria.

Note: Until recently, Fechtner-Epstein syndrome(hereditary nephritis, deafness, cataracts, and May-Hegglin anomalies) was also considered a genetic variant of Alport syndrome. It is now known that this syndrome is a genetic mutation in the MYH9 gene for the myosin heavy chain and is no longer classified as Alport's syndrome.

Diagnosis



Diagnosis consists of:

Electron photography of the basement membrane of the glomerulus

- Physical examination and anamnesis.
- Detailed family history and possible analysis of urine in close relatives.
- Immunohistochemical examination of the basement membrane in renal or skin biopsy.
- Examination of renal biopsy using an electron microscope.
- Molecular genetic testing of the COL4A3, COL4A4 and COL4A5 genes.

If a doctor discovers **microscopic hematuria**, Alport's syndrome should always be considered.

- **Clinical signs supporting suspected Alport syndrome:**
 - Renal - microhematuria, proteinuria, hypertension and renal insufficiency.
 - Hearing - bilateral hearing loss at high frequencies.
 - Ocular - anterior lenticon (15-20% of cases), perimacular hyperpigmentation (30% of cases).

Family history

Often hematuria, deafness and / or terminal stages of renal failure.

- **Clinical signs supporting suspicion of thin basement membrane syndrome:**
 - Persistent haematuria without renal failure in both the affected individual and the family history

Therapy

Treatment is symptomatic and consists of correction of blood pressure and reduction of proteinuria (ACE inhibitors and / or angiotensin receptor blockers). The only possible therapy for end-stage renal disease in Alport's syndrome is currently hemodialysis or kidney transplantation. Gene therapy treatment is being considered in the future.

History

This congenital disease was described in 1927 by Dr. Cecil A. Alport thanks to a family in which men affected by deafness and progressive nephropathy were present for several generations. The essence of the disease was not discovered until the 1970s.

References

References

External links

- An article about the COL4A5 gene in the OMIM database (<http://omim.org/entry/303630>)

References

- POVÝŠIL, Ctibor – ŠTEINER, Ivo. *Speciální patologie*. 2. edition. Praha : Galén : Karolinum, 2007. 430 pp. ISBN 978-80-7262-494-2.
- ČEŠKA, Richard. *Interna*. 1. edition. Praha : TRITON, 2010. 855 pp. ISBN 978-80-7387423-0.
- -. *Collagen IV-Related Nephropathies* [online]. ©28. srpna 2001. The last revision 15. července 2010, [cit. 2011-03-06]. <<https://www.ncbi.nlm.nih.gov/books/NBK1207/>>.