

Adnate HSV infection

Adnate infection with herpes simplex virus (HSV) mainly affects newborns of mothers with herpes genitalis infection. HSV is mainly transmitted vertically during childbirth, rarely also transplacentally. Most at risk are newborns of mothers with asymptomatic primary infection (i.e. without seeding of vesicles), which occurs in up to 3/4 of cases. Adnate HSV infection can appear at any time in the first 6 weeks of life. It takes place under the guise of a localized infection of the skin, eyes and mouth or under the guise of a severe generalized form or CNS infection. It is treated with intravenous aciclovir. It has a poor prognosis (severe permanent consequences, high mortality). For women with recurrences of genital herpes, preventive treatment with aciclovir is recommended from the 36th week of pregnancy until delivery. HSV infection should be ruled out as soon as possible in any neonate with seeding vesicles.^[1]

Etiopathogenesis

Herpes simplex virus (HSV) belongs to the Herpesviridae family. It contains a double-stranded linear DNA (dsDNA) genome composed of 150,000 base pairs that encodes more than 80 polypeptides. The capsid of the virus is composed of 162 capsomeres, covered by a matrix and a capsule composed of 11 glycoproteins, lipids and polyamines. All viruses are characterized by the ability of latency and reactivation, which causes recurrent infections.^[2] Glycoproteins (gB, gC, gD, and gE) allow the virus to attach to host cell receptors, enter cells, and evade the immune response. HSV is capable of attacking a variety of cell types including epithelial and neural cells. When nerve cells are attacked, latent infection or destruction of neurons and glial cells occurs. The invasion of the epithelium leads to the destruction of cells with the formation of vesicles that contain a large number of viruses.^[3]

HSV enters the human body through the mucous membrane of the mouth, genitals or conjunctiva or through the skin. It attacks the sensory nerve endings and retrogradely travels the axons to the ganglia of the posterior roots of the spinal cord, where they remain until the end of life and can be reactivated. The latent virus is not sensitive to antiviral treatment and the infection is therefore lifelong.^[2]

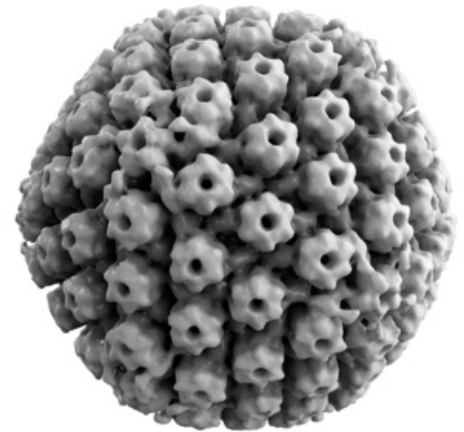
The herpes simplex virus is transmitted to newborns most often **vertically during childbirth**. Newborns of mothers with asymptomatic **primary herpes genitalis infection** are most at risk of genital HSV infection. In full-term infants, the risk of HSV transmission is 25-60% for primary maternal infection and only about 2% for recurrent infection. Newborns can also become infected with HSV-1 if the mother has a primary active HSV-1 infection at the time of delivery, usually in the throat or mouth. Furthermore, newborns can become infected while breastfeeding from an infected breast. The fetus can become infected transplacentally or ascendant when the fetal membranes are broken.^[1]

Genital HSV infection is one of the most common sexually transmitted infections. It is most often caused by the type HSV-2, less often by HSV-1. 3 clinical entities are distinguished: primary genital HSV (the person has no antibodies), non-primary first episode of genital HSV (the person already has antibodies against another type of HSV) and recurrent genital HSV (the person already has antibodies against the same HSV as in the vesicles). Primary genital HSV usually presents with painful vesicles that may be accompanied by itching, dysuria, vaginal discharge, and enlarged local lymph nodes. Fever, malaise, and myalgia may occur one to two days before seeding of the lesion.^[3]

Clinical image

There are 3 clinical forms:

1. **localized infection of the skin, eyes, mouth** (SEM – skin, eye, mouth) – 45% of cases of secondary HSV infection,
 - skin lesions (papules → vesicles → ulcers) with a diameter of 1-3 mm and an erythematous background most often in the head area (or on the buttocks in the position of the pelvic end), but they can appear anywhere on the body,
 - in some children with SEM, only the mucous membrane of the mouth or the conjunctiva may be affected without the skin being affected,
 - manifestations usually in the 1st to 2nd week of life,
 - zero mortality, but without treatment it can progress to a disseminated form or to the CNS;
2. **disseminated infection** that affects many organs, especially the liver and lungs - 25% of cases,
 - manifestations usually in the 1st to 2nd week of life,
 - general symptoms are the same as in bacterial sepsis: fever, thermolability, lethargy, feeding problems, respiratory distress, and cyanosis; as the infection progresses, DIC, hepatitis, pneumonitis and convulsions may follow,



3D reconstruction of the HSV-1 capsid

- poor prognosis, high mortality;
3. **CNS infection** with or without skin involvement - 30% of cases,^[1]
- manifestations usually in the 2nd to 3rd week of life,
 - generalized or localized convulsions, pulsating fontanelles, irritability, abnormal movements or postures;
 - abnormal EEG recording (convulsive activity or abnormal background),
 - changes on brain imaging approximately 5 days apart (typically in the temporal lobes, insula cortex and gyrus rectus region),
 - poor prognosis – serious permanent consequences (delayed psychomotor development, learning disabilities, cerebral palsy, blindness and convulsions).^{[3][1]}

Transplacentally acquired infection accounts for about 5% of neonatal HSV infections. It is manifested by skin vesicles or scarring, chorioretinitis, hydrocephalus, microphthalmia, microcephaly. It is often associated with low birth weight due to prematurity or intrauterine growth restriction.^[3]

Diagnosis

- the diagnostic method of choice is PCR, especially in CNS involvement (sensitivity in cerebrospinal fluid is 70-100%, in serum it is lower), PCR can be performed from blood, cerebrospinal fluid, and from lesions on the skin and mucous membranes;
- culture of virus in smears from skin lesions, oropharynx, nasopharynx, conjunctiva, rectum, blood and urine;
- auxiliary examinations: liver enzymes, ophthalmological examination, lumbar puncture, possibly MRI or CT imaging;
- examination of the level of antibodies can be used to differentiate between primary infection of the mother and recurrence.^{[1][3]}

Therapy

- aciclovir i.v. (60 mg/kg/day), usually for 14 to 21 days;
 - disrupts HSV DNA replication;
 - side effects: neutropenia, nephrotoxicity;
 - early initiation of treatment significantly reduces morbidity and mortality;
 - it is recommended to be administered even in localized (SEM) infection due to its risk of transition to a generalized or CNS infection.^[1]

Cutaneous recurrences occur in about 50% of cases, therefore, in some cases, after acute treatment, long-term suppressive treatment with aciclovir for 6 months with regular monitoring of neutrophil counts is given.^[1]

Prevention

For women with recurrences of herpes genitalis, preventive administration of aciclovir is recommended from the 36th week of pregnancy until delivery.

In case of primary infection of a pregnant woman or active lesions in the genital area, a caesarean section is recommended before the membranes rupture (i.e. before the amniotic fluid drains).^[1]

Sources

Related articles

- Herpes simplex virus • Genital herpes • Encephalitis caused by herpes simplex viruses • Gingivostomatitis herpetica
- Infection endangering the fetus: Congenital syphilis • Congenital toxoplasmosis • Congenital listeriosis • HBsAg positive mother and newborn • HIV infection in pregnancy • The importance of chlamydia and mycoplasmas in perinatology • Congenital cytomegalovirus infection
- Infections in the neonatal period

External links

- Herpes – video by Osmosis (video na YouTube v angličtině s anglickými titulky) (<https://www.youtube.com/watch?v=IxLhUDI3z60>)
- Herpes genitalis v graviditě – management – Doporučený postup ČGPS ČLS JEP (2013) (<http://www.perinatologie.cz/dokumenty/doc/doporucene-postupy/p-2010-herpes-genitalis-v-gravidite.pdf>)
- Bartošová D.: Prevence a léčba infekcí vyvolaných virem Herpes simplex a Varicela zoster v dětském věku (2008) (<https://www.pediatricpropraxi.cz/pdfs/ped/2008/06/10.pdf>)

References

1. POLIN, Richard – SPITZER, Alan. *Fetal and Neonatal Secrets*. 3. edition. Elsevier Health Sciences, 2013. pp. 360-363. ISBN 9780323091398.
2. https://www.uptodate.com/contents/neonatal-herpes-simplex-virus-infection-clinical-features-and-diagnosis?topicRef=6040&source=see_link

3. PARKER, L A. *Medscape* [online]. Medscape, ©2004. [cit. 2018-11-07]. <https://www.medscape.com/viewarticle/472408_1>.