

Adductor magnus muscle

Origin:

first part: tuber ischiadicum

second part: ramus inferior ossis pubis, ramus ossis ischii,

Insertion:

first part: labium mediale lineae asperae,

second part: epicondylus medialis femoris

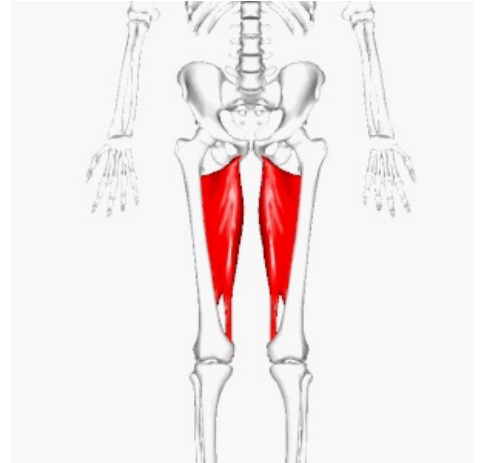
Innervation:

first part: nervus ischiadicus

second part: nervus obturatorius

Between the two parts *m. adductor magnus* gives rise to the *hiatus adductorius*, which is the entrance to the *canalis adductorius*.

Function: adduction, extension, auxiliary internal and external rotation (according to fibers) in the hip joint.



Adductor magnus muscle

Links

References

- ŠIHÁK, Radomír – GRIM, Miloš. *Anatomy*. 2nd, edit. and add edition. Grada Publishing, 2002. 470 pp. vol. 1. ISBN 80-7169-970-5.
- VIGUÉ, Jordi. *Atlas of the Human Body*. 3. edition. Rebo, 2007. ISBN 978-80-7234-881-7.