Acute thyroiditis

Acute thyroiditis (suppurative thyroiditis) is currently a relatively rare infectious purulent inflammation of the thyroid gland.

Etiology

It is usually caused by a **bacterial inflammatory condition** in the orofacial area or by septic metastasis in immunocompromised persons, or it may have a **tuberculous origin**.

The clinical picture

- Local redness above the thyroid gland;
- palpable pain;
- fever.

Diagnosis

The clinical picture is the basis for diagnosis. The laboratory findings include increased **sedimentation**, **leukocytosis**, and **high** CRP. The imaging methods used are: USG and thin needle aspiration biopsy (FNAB).

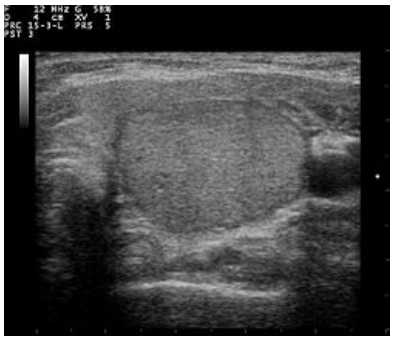

Ultrasound examination of the thyroid gland

Therapy

Broad-spectrum antibiotics in high doses, but best targeted after culture examination.

References

Related Articles

- Subacute thyroiditis
- Chronic (autoimmune) thyroiditis
- Inflammation of the thyroid gland

References

- ČEŠKA, Richard – ŠTULC, Tomáš, et al. *Interna.* 2. edition. 2015. 909 pp. ISBN 978-80-7387-895-5.