

Acute mediastinitis

Acute mediastinitis is a serious disease with a high lethality (approximately 50%).

- Usually a consequence of perforation of the oesophagus (endoscopic procedures, tumours), rarely a complication of pneumonia/mediastinitis (possibly lung abscess, empyema) or even as a complication of coemphysitis.

Clinical picture

- Fever with retrosternal pain,
- with esophageal perforation dysphagia + subcutaneous emphysema,
- X-ray: enlargement of the mediastinum, ev. with pleural effusion + mediastinal emphysema.

Therapy

- ATB i.v., mediastinal drainage.

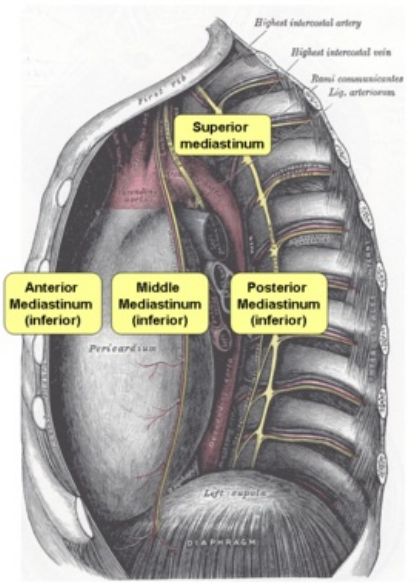
References

Related articles

- Mediastinum
- Chronic mediastinitis

References

- DÍTĚ, P., et al. *Vnitřní lékařství*. 2. edition. Praha : Galén, 2007. ISBN 978-80-7262-496-6.



Anatomy of the mediastinum