

Ureter

Ureter is shaped like a slightly flattened tube of about 4–7 mm diameter. It has variable length, but average might be around 30 cm. It is about 1 cm shorter in the female.

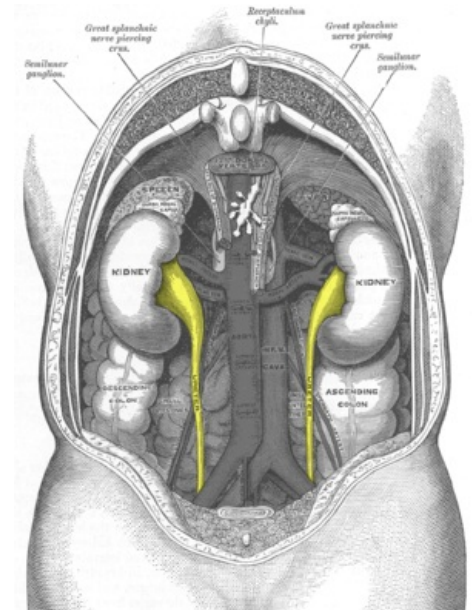
Syntopy of ureter

- Runs inferiorly from the apex of the renal pelvis at the hilum.
- Passes over the pelvic brim at the bifurcation of the common iliac artery.
- Runs along the lateral wall of pelvis and enters the urinary bladder.
- Abdominal parts adhere closely to the parietal peritoneum and are retroperitoneal throughout their course.
- Three constrictions:
 1. At junction between renal pelvis and ureter.
 2. At crossing of brim of pelvic inlet.
 3. During passage through wall of urinary bladder.

Vasculature of ureter

- **Abdominal portion:** branches from renal arteries, abdominal aorta and common iliac artery.
- **Pelvic portion:** branches from superior vesical aa, middle rectal aa, uterine/vaginal (female), inferior vesical artery (male).

Veins: follow the arteries in the same way and drain into renal and testicular (ovarian) veins.



Syntopy of ureters.

Links

Related articles

- Kidney
 - Renal Blood Vessels and Renal Segments
 - Structure of Kidney

Bibliography

- MOORE, Keith L – DALLEY, Arthur F. *Clinically Oriented Anatomy*. 5. edition. Lippincott Williams & Wilkins, 2005. ISBN 0781736390.