

Teres Minor

English: *Teres minor muscle*

Latin: *Musculus teres minor*



Teres minor muscle (lat. *musculus teres minor*) is a narrow muscle of the upper limb. It arises from the lateral border of the scapula and goes to greater tubercle of the humerus (*tuberculum majus humeri*). It is innervated by the axillary nerve.

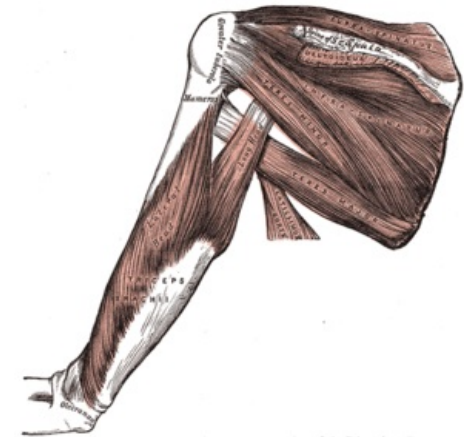
Links

Related articles

- Pectoralis Major
- Deltoid Muscle

Further reading

- PETROVICKY, Pavel, et al. *Anatomie s topografií a klinickými aplikacemi : Sv. 1, Pohybové ústrojí*. 1. edition. Martin : Osveta, 2001. 463 pp. ISBN 80-8063-046-1.



Teres minor muscle