

Scalene Fissure

English: *Scalene fissure*
Latin: *Fissura scalenorum*



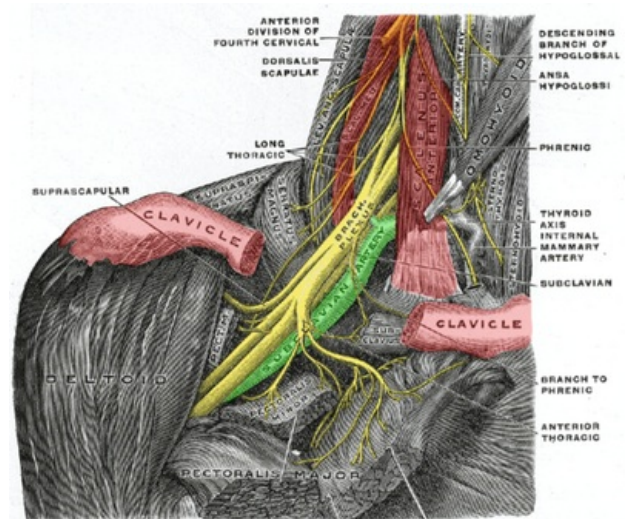
The **Scalene fissure** is a triangular hiatus found in the neck.

Borders

- **Anteriorly:** Scalenus anterior
- **Posteriorly:** Scalenus medius
- **Caudally:** First rib

Contents

- Brachial plexus
- Subclavian artery
- Subclavian vein (anterior to the triangle)



Scalene fissure (borders in red)

Links

Bibliography

- GRIM, Milos – DRUGA, Rastislav. *Zaklady anatomie 5 : Anatomie krajiny tela*. 1. edition. 2002. ISBN 978-80-7262-179-8.