

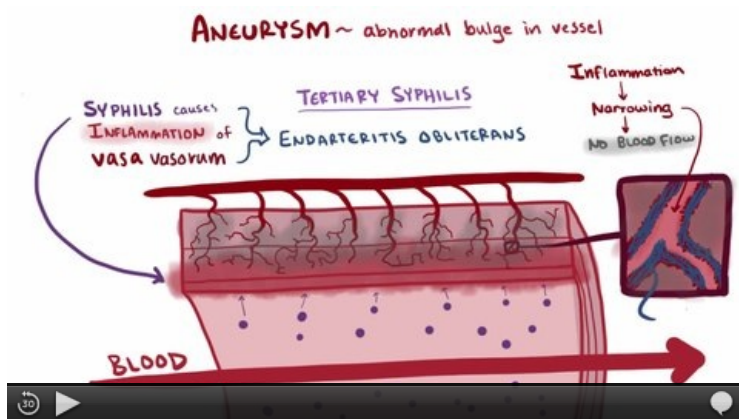
Aneurysm

An **aneurysm** is a limited enlargement of an artery (bulge) caused by structural changes in its wall. It can affect any artery, most often the aorta, femoropopliteal region and arteries of the Willis circuit. Organ aneurysms are less common - hepatic artery, renalis artery, carotid artery. Types of aneurysms: a) sac-shaped b) spindle-shaped c) shuttle-shaped d) serpentine e) diffuse f) dissecting g) false

Causes

1. **Processes in the vessel wall** - atherosclerosis, syphilis, cystic medionecrosis, PAN, fungal embolism;
2. **arosis** of the outside - tuberculosis (Rasmussen's aneurysm), peptic ulcer, tumor;
3. **injury**;
4. **congenital inferiority of the vascular wall** (aneurysma congenitum).

About 75% of aneurysms (mainly aortic) have no atherosclerosis. Decreased amounts of collagen, elastin, increased activity of collagenases and elastases (α 1-antitrypsin deficiency - often associated with emphysema) were found.



Definition, pathogenesis, symptoms, complications, treatment.

Division

- **True (*verum*)** - it is formed by a simple arching of the wall (by the action of intra-arterial blood pressure, the wall is formed by the entire wall of the artery).
- **False (*spurium*)** - it is caused by rupture of the wall (periarterial hematoma), usually post-traumatic or postoperative, part of the artery is defective and blood leaks into the environment, where it borders the ligament.
- **Dissecting (*dissecans*)** - intramural hematoma.
- **Arteriovenous (*arteriovenosum*)** - fistula between artery and vein.

True aneurysm

By the morphology we divide aneurysmata to:

- sac-like(*saccatum*),
- boat-like(*naviculare*),
- spindle(*fusiforme*),
- diffuse(*diffusum*),
- serpentine(*serpentinum*).

The most common localizations of right aneurysms (mostly vesicles) are the *aorta* and arteries of the Willis circuit. **The cause in the aorta is syphilitic mesoaortitis (thoracic aorta) and atherosclerosis (abdominal aorta). In the arteries of the brain, it is a congenital inferiority of the vascular wall (however, the aneurysms themselves are not congenital, ie they are not present at birth, they develop gradually due to hypertension).**

Aortic aneurysm

It is usually diagnosed according to a chest X-ray (even randomly), we clarify it by CT or MRI, sonography is not very beneficial, angiography does not determine the actual size (often aneurysms are filled with a thrombus).

Thoracic aorta aneurysm

Based on luetic mesoaortitis in III. stage syphilis. The maximum changes are in the medium - inflammatory infiltration, ischemic defects of elastic and muscle during obliteration of nutritional vessels in the adventitia (thickened fibrous). Vasa vasorum are thick-walled with fibrous thickening of the intima (endarteritis obliterans). The lesions in the medium heal with scars that wrinkle the intima - macroscopically the appearance of "hand wash" or "tree bark". It is most often located in the ascending part and in the aortic arch. A possible complication (in addition to the formation of an aneurysm and its collapse into the pericardial cavity with subsequent cardiac tamponade) is aortic valve involvement - ectasia with aortic insufficiency (hypertrophy and dilatation of the left ventricle) and **narrowing of coronary arteries** - ischemia to myocardial infarction. Thoracic aortic aneurysm exerts pressure on the surrounding structures - trachea and bronchi (difficulty breathing), esophagus (dysphagia), recurrent laryngeal nerve (speech problems).

Lumbar aorta aneurysm

Based on atherosclerosis. It affects various lengths of the aorta. From the distance of the renal arteries to the bifurcation and further to the common iliac arteries. Risk of rupture with a diameter over 6 cm - hemoperitoneum. Aneurysms are often filled with a stratified thrombus.

Willis circuit aneurysm

Localized most often at the site of arterial branching. Diameter 5–20 mm, spherical shape (blueberry aneurysms).

Aneurysm of periferral vessels

Most often atherosclerotic (less often post-traumatic or fungal). Localization - a. Poplitea, subclavia, carotid. They are almost always indicated for resection (frequent embolic complications).

Lower limb

Aneurysm of the femoral artery - a throbbing arch with a murmur under the groin, can suppress a vein and nerve. Aneurysm of the popliteal artery - common, embolization, compression of a vein and nerve (n. Tibialis).

Upper limb

Aneurysm of the subclavian artery - as poststenotic dilatation in TOS, resistance, murmur above the clavicle, frequent embolizations. First, resection of the first rib is performed (TOS solution), only then exclusion of the bulge and bypass with a venous graft.

False aneurysm

It is a **periarterial hematoma caused by rupture of the artery**. It remains partly fluid and communicates with the lumen of the artery. The wall of the false aneurysm is formed by surrounding tissues compressed by the hematoma. Part of the blood clots and the border forms a thrombus, which it later organizes, and the wall is formed by a ligament. It affects any artery. With the constant flow of blood from the lumen of the vessel, the aneurysm can further enlarge and later collapse into a body cavity.

Disecting aneurysm

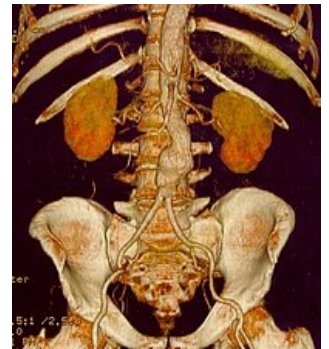 For more information see *Dissection of the thoracic aorta*.

It is an **intramural hematoma** that penetrates a crack in the intima into the medium and further **spreads through the vessel wall** at various distances antegrade and retrograde. It most often affects the aorta. The entrance defect (transverse or oblique crack 3-5 cm long) is located in 90% of the ascending part (type Stanford A), in 10% only after the distance between the left and subclavian artery (type Stanford B). The medium is usually split at the interface of the outer and middle third and affects 2/3 to 3/4 of the aortic circumference. It can spread forward to the site of bifurcation, retrogradely to the aortic valve. It often passes into arteries leaving the aorta (coronary arteries - myocardial infarction, carotid arteries - ischemia of the brain, subclavia and iliac - pulseless state, abdominal arteries - ischemia of the intestine, renal arteries - hematuria). It has a tendency to collapse - either back into the lumen of the aorta (so-called reentry, there are two lumens in the aorta - right and false) or outside. Rolling on the outside is fatal. It most often occurs in the initial section of the aorta with the development of hemopericardium and cardiac tamponade, less often it develops hemothorax or hemoperitoneum.

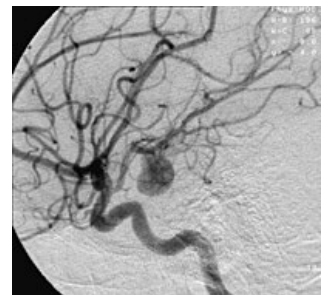
Predispositions for aortic dissection are: hypertension, cystic medionecrosis, congenital connective tissue disorders (Marfan's, Ehlers-Danlos syndrome), aortic bicuspid aortic valve, aortic coarctation, late pregnancy.

Complications

- **aortic involvement** (intramural hematoma narrows the original lumen);
- **involvement of arteries leaving the aorta** (ischemia of areas supplied by them);
- **aortic valve insufficiency;**



Abdominal aortic aneurysm in CT scan



Cerebral artery aneurysm

- **rupture of aorta**;
- **heart failure** (high resistance of the false lumen).

Arteriovenous aneurysm

Patological linkage of vein and artery . Arteriovenous shunt burdening the heart leading to heart failure.

1. **Congenital**– a ball of arteries, capillaries and veins, common in the brain.
2. **Acquired**– penetrating wound affecting the artery and the adjacent vein. Penetration of an arterial aneurysm into an adjacent vein, inflammatory necrosis of adjacent vascular walls.

Mycotic aneurysm

It arises either from an **endogenous infection** (in bacteremia in which the aorta, femoral or popliteal artery is affected) or from an **exogenous infection**, from a **penetrating injury - catheterization**, addicts, most often affected by the femoral artery, brachial artery and radial artery. Infection can also occur through the vasa vasorum or by attachment to atherosclerotic plaques.

Weakening of the wall leads to dilation to rupture, less often the aneurysm is filled with a thrombus, which becomes infected and produces septic emboli (salmonella, staphylococci, E. coli).

The clinical picture is given by a septic condition with fever, chills, fatigue, leukocytosis, positive blood culture.

Therapy– ATB therapy, resection of the aneurysm, if revascularization is required, almost always by venous graft (arterial reinfects rapidly).

Therapy of aneurysm

- **Endovascular**– zavedení graft-stentu endoluminální cestou;
- **operational**:
 - *inkluzní* – vštíí cévní protézy (aorto-aortální, aorto-biliacká, aorto-bifemorální);
 - *exkluzní* – *obchvat aneurysmatu (podvážse se) bypassem* – *hlavně na končetinách*.

Only 7% of patients survive the conservative procedure over five years, and 60% of patients survive the operation. The operation is very demanding. Possible complications are respiratory insufficiency, cardiac and renal failure, DIC, paraplegia.

Complications

Once created, the aneurysm progressively enlarges (the larger it is, the faster it enlarges) and there is a risk of **rupture**. Turbulent flow occurs in the aneurysm - the formation of **thrombi**, followed by **embolization**.

References

Related articles

- Cerebral artery aneurysm
- Hemorrhage
- Thrombosis
- Abdominal aortic aneurysm
- Dissection of the thoracic aorta
- Atherosclerosis

External sources

- Aneurysma (<https://www.youtube.com/watch?v=FgcHtmry3iA>)

Source

- BENEŠ, Jiří. *Studijní materiály* [online]. [cit. 17.5.2010]. <<http://jirben.wz.cz>>.

Literature

- ZEMAN, Miroslav, et al. *Speciální chirurgie*. 2. edition. Praha : Galén, 2006. vol. 575. ISBN 80-7262-260-9.